

Robotic treatment of colorectal endometriosis: technique, feasibility and short-term results

A. Ercoli^{1,*}, M. D'asta¹, A. Fagotti², F. Fanfani², F. Romano¹,
G. Baldazzi³, M.G. Salerno⁴, and G. Scambia²

¹Department of Gynecology, Policlinico Abano Terme, Piazza Cristoforo Colombo, 1- 35031 Abano Terme (PD), Italy ²Department of Gynecology, Catholic University, L.go A. Gemelli, 100168 Rome, Italy ³Department of Surgery, Policlinico Abano Terme, Piazza Cristoforo Colombo, 1- 35031 Abano Terme (PD), Italy ⁴2nd Department of Obstetrics and Gynecology, Santa Chiara Hospital, Via Roma, 67- 56100 Pisa, Italy

*Correspondence address. Tel: +39-049-8221354; Fax: +39-049-8221363; E-mail: alfercoll@yahoo.it

Submitted on August 2, 2011; resubmitted on October 18, 2011; accepted on November 17, 2011

BACKGROUND: Deep infiltrating endometriosis (DIE) is a complex disease that impairs the quality of life and the fertility of women. Since a medical approach is often insufficient, a minimally invasive approach is considered the gold standard for complete disease excision. Robotic-assisted surgery is a revolutionary approach, with several advantages compared with traditional laparoscopic surgery.

METHODS: From March 2010 to May 2011, we performed 22 consecutive robotic-assisted complete laparoscopic excisions of DIE endometriosis with colorectal involvement. All clinical data were collected by our team and all patients were interviewed preoperatively and 3 and 6 months post-operatively and yearly thereafter regarding endometriosis-related symptoms. Dysmenorrhoea, dyschezia, dyspareunia and dysuria were evaluated with a 10-point analog rating scale.

RESULTS: There were 12 patients, with a median larger endometriotic nodule of 35 mm, who underwent segmental resection, and 10 patients, with a median larger endometriotic nodule of 30 mm, who underwent complete nodule debulking by colorectal wall-shaving technique. No laparotomic conversions were performed, nor was any blood transfusion necessary. No intra-operative complications were observed and, in particular, there were no inadvertent rectal perforations in any of the cases treated by the shaving technique. None of the patients had ileostomy or colostomy. No major post-operative complications were observed, except one small bowel occlusion 14 days post-surgery that was resolved in 3 days with medical treatment. Post-operatively, a statistically significant improvement of patient symptoms was shown for all the investigated parameters.

CONCLUSIONS: To our knowledge, this is the first study reporting the feasibility and short-term results and complications of laparoscopic robotic-assisted treatment of DIE with colorectal involvement. We demonstrate that this approach is feasible and safe, without conversion to laparotomy.

Key words: deep endometriosis / colorectal endometriosis / robotic-assisted laparoscopy

Introduction

Deep infiltrating endometriosis (DIE) is a complex disease affecting women of reproductive age impairing their quality of life and their fertility (Chapron *et al.*, 2003). In particular, the estimated incidence of bowel endometriosis is between 3 and 36% (Jerby *et al.*, 1999) and the rectum and the rectosigmoid junction together account for 70–93% of all intestinal lesions (Coronado *et al.*, 1990; Bailey *et al.*, 1994). Other bowel localizations are relatively rare (Brouwer and Woods, 2007). In a small percentage of cases, women are asymptomatic, but for the vast majority of them, it can cause dysmenorrhea,

dyspareunia, dyschezia, dysuria, tenesmus and painful defecation or occlusion impairing their quality of life. When severe DIE is presented, a medical approach is often insufficient, meaning that surgery is considered the most effective treatment (Landi *et al.*, 2004; Pereira *et al.*, 2009; Pandis *et al.*, 2010). When DIE of the sigmoid-rectum is presented, the involvement of the rectal wall can involve the serosa up to the mucosa (Roman *et al.*, 2009), so that to ensure a complete excision and the best results in terms of symptom relief and recurrence rate, intestinal surgery with or without segmental resection may be required. To obtain complete disease excision, a minimally invasive approach is now considered the gold standard for this kind of surgery

and a multidisciplinary approach involving urologists and colorectal surgeons is essential for correct management (Seracchioli et al., 2010). Robotic surgery is a revolutionary minimally invasive approach, with several advantages compared with traditionally laparoscopic surgery, due to the high-definition 3D vision system and to the specific instrument articulation, with greater precision, absence of tremor and excellent outcomes (Nezhat et al., 2010). Robotics have been used successfully in many fields of gynecological surgery, with increasing prospects (Goldberg and Falcone, 2003; Nezhat et al., 2006; Field et al., 2007; Nezhat et al., 2009). Nezhat et al. reported for the first time a comparison of robotic with the classical laparoscopic approach for treating endometriosis. Despite the very small number of stage IV endometriosis patients included in their study, the authors concluded that the robotic system could be useful to obtain an adequate debulking of disease without conversion to laparotomy.

We present here our experience of 22 consecutive patients affected by severe DIE with colorectal involvement, and treated with the laparoscopic robotic-assisted da Vinci Surgical System.

Materials and Methods

Patients

From March 2010 to May 2011, at the Department of Obstetrics and Gynecology of 'Policlinico Abano Terme' Hospital, Abano Terme, Italy, we performed 22 consecutive robotic-assisted laparoscopic complete excisions of DIE endometriosis with colorectal involvement. Before surgery, patients underwent pelvic and abdominal examination, a transvaginal pelvic ultrasound scan, abdominal magnetic resonance imaging, a barium enema and eventual rectocolonoscopy according to their clinical data. All clinical data were collected by our team and all patients were interviewed preoperatively about endometriosis-related symptoms. Dysmenorrhea, dyschezia, dyspareunia and dysuria were evaluated with a 10-point analog rating scale (0 absent, 10 unbearable) and gastrointestinal symptoms were assessed as well. Eventually hormonal therapy was stopped 1 month before surgery. All of our patients reported at least two of these symptoms and were not responsive or not interested in medical therapy. An intestinal resection was preoperatively planned in the case of endometriotic implants into the rectal mucosa at rectocolonoscopy and when more than one intestinal stricture was found with the barium enema.

Patients ate a fiber-free diet for at least 3 days before surgery. The day before surgery, all patients received a mechanical bowel preparation with 3–4 l of polyethylene glycol. Prophylactic antibiotic therapy with cefazolin 2 g was given at the beginning of the operation and metronidazole was given only to patients submitted for bowel and/or vaginal resection. Antibiotic therapy was maintained for 5 and 7 following days in non-resected and resected patients, respectively. The operation time was calculated from anesthesia induction to patient awakening, and estimated blood loss was calculated by measuring aspirated blood volume (Table I). In those cases with bowel resection, a drainage catheter was left near the anastomosis and it was removed first signs of recovery of bowel function. Those patients without bowel resection had clear fluids 12 h after the procedure and started eating 24 h after the procedure except for two cases who had total parenteral nutrition for 4 days. Patients submitted for bowel segmental resection had 5 days with total parenteral nutrition and nil by mouth. We followed up all patients at 3 and 6 months post-operatively and yearly thereafter with pelvic examination, a clinical interview regarding symptoms and eventually a pelvic ultrasound scan. Post-operative hormonal therapy, consisting of continuous low-dose

Table I Surgical and anatomopathologic findings.

Variable	Data
Resected patients (n = 12)	
Operative time, median (range), min	370 (260–720)
Main nodule, larger axis, median (range), mm	35 (24–44)
Estimated blood loss, median (range), ml	100 (50–250)
Type of bowel resection	
Sigmoid	2
Rectosigmoid	9
Rectum	1
Length of bowel resection, median (range), cm	13 (10–18)
Type of anastomosis	
High (>8 cm)	1
Medium/low (5–8 cm)	9
Ultra-low (≤5 cm)	2
Temporary ileostomy/colostomy	0
Associated vaginal resection	7
Associated ureteral resection and reimplantation	1
Non-resected patients (n = 10)	
Operative time, median (range), min	280 (220–365)
Nodule, larger axis, median (range), mm	30 (18–38)
Estimated blood loss, median (range), ml	200 (100–350)
Inadvertent intraoperative rectal perforation	0
Temporary ileostomy/colostomy	0
Associated vaginal resection	6

monophasic oral contraceptives for 6 months, was prescribed in all cases with the exception of those seeking pregnancy.

Surgical technique

The robotic procedure was performed with the patient in a gynecologic position under endotracheal general anesthesia. A bladder catheter was placed to empty the bladder and control the urine output, and a uterine manipulator was placed through the cervix to manipulate the uterus. All the procedures were performed throughout the open laparoscopy technique through an umbilical access, or a right paraumbilical access in the case of a planned intestinal resection. After induction of pneumoperitoneum and insertion of the robotic videolaparoscope, we explored the entire abdominal cavity to evaluate the extension of endometriotic lesions and then two robotic trocars (8 mm) and two assistant trocars (5 and 12 mm) were introduced (Fig. 1). Then robot docking was performed and the primary surgeon controlled the robot remotely from the console. The robotic instruments used during the procedure included monopolar scissors, bipolar forceps, a monopolar hook and one large needle holder. All the procedures were performed with a nerve-sparing approach mediated by our previous studies on female pelvic surgical anatomy and radical pelvic surgery for neoplasia (Ercoli et al., 2003, 2005).

In all cases, the dissection started, if necessary, with a complete, bilateral, salpingo-ovaryolysis and the eventual exeresis of endometrioma(s) and then by mobilizing the sigmoid colon and by opening the retroperitoneum for identification; the presacral fascia, the ureters, the uterine arteries and the hypogastric nerves. In the case of a planned intestinal resection, extensive mobilization of the descending colon was also performed and

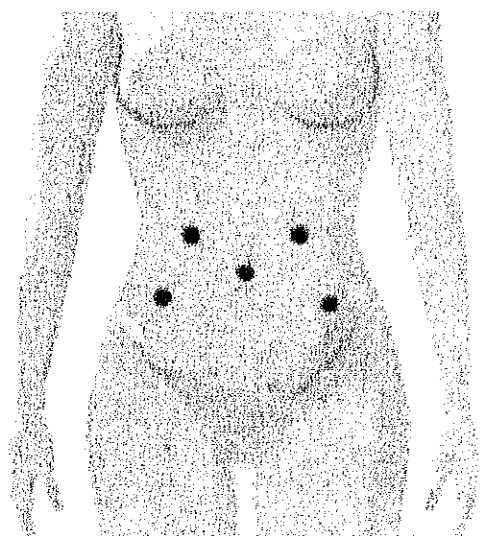


Figure 1 The placement positions of trocars. Green points represent positions of the robotic 8 mm trocars (one through the umbilicus and the other two, respectively, in the right and left iliac fossa). The red point represents a 5 mm assistant port, placed about 2–4 cm above the left costal margin. The blue point represents a 12 mm assistant port, placed about 2–4 cm above the right costal margin.

the superior rectal artery was identified. The ureters and nerves were then separated by the peritoneum and the so-called Okabayashi pararectal space was developed up to the uterosacral ligaments or the puborectal portion of the levator ani muscle according to the position and caudal extension of the nodule. A complete ureterolysis and parametrial resection was performed at this time when a lateral extension of the endometriotic nodule with involvement of periureteral/parametrial tissue was present. Then the rectum was separated from the posterior uterine wall and/or from the vagina. When an intestinal resection was not planned, we always tried first to separate the nodule from the intestinal wall by the so-called 'shaving technique' and we decided intraoperatively regarding an eventual intestinal resection. A reconstruction of the muscular portion of the rectal wall was performed in all cases involving rectal shaving by using 3/0, interrupted, absorbable monofilament sutures placed in the transverse direction to avoid narrowing the lumen. In the case of a planned intestinal resection without associated vaginal resection, we first separated the nodule from the posterior vaginal wall by the 'shaving technique' and then we removed the nodule en bloc with the resected bowel. When an intestinal resection together with a vaginal resection was planned, we transected the nodule in the middle portion and we separately remove the two half nodules, one en bloc with the resected bowel and the other en bloc with the resected vagina. In the latter situation, the vagina was resected transvaginally at the end of the robotic procedure and sutured in a single plane with interrupted, absorbable monofilament sutures. All endometriotic lesions, including those affecting the utero-sacral ligaments, torus uterinus, vagina and peritoneum, were removed. Depending on the intraoperative findings regarding the bowel wall involvement, we performed a shaving technique excision of the endometrial nodule or, together with the general surgery team using the same trocars, a bowel segmental resection with a terminal-to-terminal anastomosis. To carry out the resection anastomosis, we removed the

robot and used the same trocars to cut the distal end of the bowel and eventually completed the mobilization of the descending colon by classical laparoscopy. Then a median suprapubic incision of 4 cm was used to exteriorize the distal bowel end, to cut the proximal end extracorporeally and to create a purse for the anvil. The colon was then replaced in the pelvic cavity and the abdominal incision was closed. The terminal-to-terminal anastomosis was created in all patients by using a rectally introduced circular stapler of 29 mm. The integrity of the anastomosis was tested by filling the rectum with blue solution and by an air test in a water-filled pelvis (Nezhat *et al.*, 2005). Protective omentoplasty to reduce the risk of a rectovaginal fistula was not performed in any of the cases.

Statistical analysis

A retrospective analysis of our collected data were performed. Analysis was done of surgical details including operative time, estimated blood loss and days of hospitalization as well as of intraoperative and post-operative complications, pathological details and follow-up records. Student *t*-test was used to compare the outcomes regarding evaluation symptoms.

Results

The median age and BMI of the patients was 38 years (range: 25–45) and 21 (range: 17–25), respectively. Of the 22 (55%) patients, 12 had previous pelvic surgery for endometriosis, while 9 (41%) patients were affected by infertility. Table I shows the main data concerning surgery, associated major surgical procedures and anatomopathologic findings according to the type of surgical procedure performed. Associated vaginal resection was done in 7 out of 12 (58%) patients who underwent bowel segmental resection and in 6 out of 10 (60%) patients who underwent rectal shaving (Table I). None of the resected or non-resected patients had ileostomy or colostomy (Table I). A large variety of minor surgical procedures, including monolateral salpingo-oophorectomy (5 cases), mono and/or bilateral ovarian cystectomy (16 cases), resection of adenomyosis nodule(s) (2 cases) and myomectomy (2 cases), were also performed in 20 out of 22 (91%) patients (data not shown). In none of the patients was a laparotomic conversion performed. The median operative times and the median intraoperative blood loss volumes were 370 and 280 min and 100 and 200 ml in resected and non-resected patients, respectively (Table I). The median operative time included the time spent for the robot docking, troubleshooting and disassembly, which required a median of 20 min (range: 12–28 min) in both groups. The median larger axis of the excised nodule was 35 and 30 mm in resected and non-resected patients, respectively (Table I). No intraoperative complications were observed and, in particular, in none of the cases treated by the shaving technique, we had an inadvertent rectal perforation. None of the patients required blood transfusion either intra- and/or post-operatively (data not shown). Table II shows the main post-operative clinical data and complications requiring hospital readmission. We readmitted one patient who had undergone segmental bowel resection and who presented with a small bowel occlusion 14 days post-surgery. This case was resolved in 3 days with medical treatment. No other major post-operative complications, such as transient or persistent urinary retention, late perforation, anastomotic fistula or leakage or rectovaginal fistula, were observed (data not shown). Data about pre- and post-operative symptoms, such as dysmenorrhea, dyspareunia, dyschezia and dysuria for the 19 patients available at the 6-months post-operative follow-up are shown Table III. A statistically

Table II Post-operative findings.

Variable	Data
Resected patients (n = 12)	
Median hospital stay, days (range)	8 (6–10)
Median bladder catheter, days (range)	1 (1–10)
Median time to resume urinary function, days (range)	1 (1–10)
Median time to resume bowel function, days (range)	6 (5–8)
Hospital readmission, (%)	1 (5%)
Non-resected patients (n = 10)	
Median hospital stay, days (range)	5 (4–7)
Median bladder catheter, days (range)	1 (1–3)
Median time to resume urinary function, days (range)	1 (1–2)
Median time to resume bowel function, days (range)	3 (2–5)
Hospital readmission	0

Table III Pre- and post-operative symptoms on VAS analogue scale for 19 patients available at the 6 month follow-up.

	Pre-operative	Post-operative	P
Dysmenorrhea, median (range)	10 (7–10)	1 (0–4)	<0.05
Deep dyspareunia, median (range)	9 (7–10)	0 (0–2)	<0.05
Dyschezia, median (range)	6 (3–9)	0 (0–1)	<0.05
Dysuria, median (range)	0 (0–2)	0 (0–1)	–

significant improvement of patient symptoms for all the investigated parameters was found (Table III).

Discussion

To our knowledge this is the first study reporting the feasibility, short-term results and complications of the laparoscopic robotic-assisted treatment of DIE with colorectal involvement in a large series of patients. It has been suggested that the use of the da Vinci Robotic System could have several advantages in patients affected by DIE (Nezhat et al., 2010). However, to date, only isolated cases or small series of patients with different types of DIE treated with the da Vinci Robotic System have been reported.

In this study, we demonstrate that robotic-assisted laparoscopy for complete debulking of DIE with colorectal involvement is feasible and safe without conversion laparotomy. We treated 22 consecutive patients; 12 patients with median larger endometriotic nodule of 35 mm underwent segmental resection, while 10 patients with a median larger endometriotic nodule of 30 mm underwent complete nodule debulking by the colorectal wall-shaving technique. Interestingly, in our series, a large variety of surgical procedures, including uterosacral ligament and ureteral resection, ureterolysis, excision of

rectovaginal nodule, excision of peritoneal nodules, excision of a rectal lesion using the shaving technique, segmental bowel resection and excision of posterior vaginal fornix, were performed by using the same positions of the five trocars for the different surgical teams. However, the increased number of trocars with regard to laparoscopy and their high positions, different from those in conventional laparoscopy, could be an aesthetic issue. The median operative time and hospitalization days are comparable to those reported using conventional laparoscopy (Fanfani et al., 2010; Ruffo et al., 2010). This is not surprising considering the complexity of this kind of debulking surgery which usually implies a relatively long hospitalization time. In contrast, the median blood loss and the blood transfusion rate seems to be improved (Ruffo et al., 2010). This could come as a consequence of high-definition 3D vision that improves depth perception, and by the greater precision of the micro-movement of the instruments. More precise dissections are achievable also because of the absence of tremor and the ergonomic position, guaranteeing a very comfortable operating setting for the surgeon. More precise surgery could also explain the absence of major intra- and/or post-operative complications. In particular, we have not experienced in our series of procedures, recto-vaginal fistula or bowel perforations or the need for protective ileostomy or colostomy. This is of particular relevance considering that in our series, associated vaginal resection was performed on 58% of resected patients and on 60% of non-resected patients, respectively, and that vaginal resection represents a major risk factor for recto-vaginal fistula (Darai et al., 2007). Moreover, no inadvertent rectal perforation during the shaving of the endometriotic nodule from the rectal wall was observed in our series. It is well known, in fact, that such a rectal perforation during the shaving procedure significantly increases the risk of post-operative complications. This observation led us during the study period to try rectal shaving even for very large endometriotic nodules. As a consequence the median larger endometriotic nodule axis that we removed in those patients who underwent rectal shaving is similar to that we report for patients who underwent segmental bowel resection.

The choice of the best surgical approach in the management of severe DIE is still debated. Our study supports the feasibility of robotic surgery for severe DIE, especially when rectal surgery is needed in order to obtain a successful outcome. Indications for colorectal resection or nodule excision by the shaving technique, or for other procedures such as discoid resection, are still controversial because there is no standard approach (Mereu et al., 2007). In many centers, segmental bowel resection is proposed in all cases with evidence of stenosis of the lumen or extrinsic compression of the bowel wall, or when endometriotic lesions larger than 2 cm are presented. Robotic surgery improving surgical skills could optimize the surgical management of these patients by reducing the need of segmental bowel resection and/or lowering the complication rate for procedures that are alternatives to intestinal resection such as the rectal wall-shaving technique and possibly discoid resection. However, larger studies are needed to compare robotic surgery with conventional laparoscopy and to assess the precise role of robotic surgery in the treatment of DIE.

Authors' roles

A.E., M.D., F.R., A.F. and F. F. contributed toward all work including the study design, execution, analysis, manuscript drafting and critical

discussion. G.S. and M.G.S. supervised all work, including the study design, analysis, manuscript drafting and critical discussion. G.B. contributed to the surgical procedures involving segmental bowel resection, manuscript drafting and critical discussion.

Funding

This research was partially supported by 'AKI Société de Recherche et Formation en Chirurgie Pelvienne', Paris, France and 'Fondazione Leonardo', Abano Terme, Italy.

Conflict of interest

The authors declare no conflict of interest and have nothing to disclose.

References

- Bailey HR, Ott MT, Hartendorp P. Aggressive surgical management for advanced colorectal endometriosis. *Dis Colon Rectum* 1994; **37**:747–753.
- Brouwer R, Woods RJ. Rectal endometriosis: results of radical excision and review of published work. *Aust NZ J Surg* 2007; **77**:562–571.
- Chapron C, Fauconnier A, Dubuisson JB, Barakat H, Vieira M, Breart G. Deep infiltrating endometriosis: relation between severity of dysmenorrhoea and extent of disease. *Hum Reprod* 2003; **18**:760–766.
- Coronado C, Franklin RR, Lotze EC, Bailey HR, Valdes CT. Surgical treatment of symptomatic colorectal endometriosis. *Fertil Steril* 1990; **53**:411–416.
- Darai E, Ackerman G, Bazot M, Rouzier R, Dubernard G. Laparoscopic segmental colorectal resection for endometriosis: limits and complications. *Surg Endosc* 2007; **21**:1572–1577.
- Ercoli A, Delmas V, Gadonneix P, Fanfani F, Villet R, Paparella P, Mancuso S, Scambia G. Classical and nerve-sparing radical hysterectomy: an evaluation of the risk of injury to the autonomous pelvic nerves. *Surg Radiol Anat* 2003; **25**:200–206.
- Ercoli A, Delmas V, Gadonneix P, Fanfani F, Ceccaroni M, Fagotti A, Mancuso S, Scambia G. Terminologia Anatomica versus unofficial descriptions and nomenclature of the fasciae and ligaments of the female pelvis: a dissection-based comparative study. *Am J Obstet Gynecol* 2005; **193**:1565–1573.
- Fanfani F, Fagotti A, Gagliardi ML, Ruffo G, Ceccaroni M, Scambia G, Minelli L. Discoid or segmental rectosigmoid resection for deep infiltrating endometriosis: a case-control study. *Fertil Steril* 2010; **94**:444–449.
- Field JB, Benoit MF, Dinh TA, Diaz-Arrastia C. Computer-enhanced robotic surgery in gynecologic oncology. *Surg Endosc* 2007; **21**:244–246.
- Goldberg JM, Falcone T. Laparoscopic microsurgical tubal anastomosis with and without robotic assistance. *Hum Reprod* 2003; **18**:145–147.
- Jerby BL, Kessler H, Falcone T, Milsom JW. Laparoscopic management of colorectal endometriosis. *Surg Endosc* 1999; **13**:1125–1128.
- Landi S, Barbieri F, Fiaccavento A, Mainardi P, Ruffo G, Selvaggi L, Syed R, Minelli L. Preoperative double-contrast barium enema in patients with suspected intestinal endometriosis. *J Am Assoc Gynecol Laparosc* 2004; **11**:223–228.
- Mereu L, Ruffo G, Landi S, Barbieri F, Zaccoletti R, Fiaccavento A, Stepniewska A, Pontrelli G, Minelli L. Laparoscopic treatment of deep endometriosis with segmental colorectal resection: short-term morbidity. *J Minim Invasive Gynecol* 2007; **14**:463–469.
- Nezhat C, de Fazio A, Nicholson T, Nezhat C. Intraoperative sigmoidoscopy in gynecologic surgery. *J Minim Invasive Gynecol* 2005; **12**:391–395.
- Nezhat C, Saberi NS, Shahmohamady B, Nezhat F. Robotic-assisted laparoscopy in gynecological surgery. *JSL S* 2006; **10**:317–320.
- Nezhat C, Lavie O, Lemyre M, Unal E, Nezhat CH, Nezhat F. Robot-assisted laparoscopic surgery in gynecology: scientific dream or reality? *Fertil Steril* 2009; **91**:2620–2622.
- Nezhat C, Lewis M, Kotikela S, Veeraswamy A, Saadat L, Hajhosseini B, Nezhat C. Robotic versus standard laparoscopy for the treatment of endometriosis. *Fertil Steril* 2010; **94**:2758–2760.
- Pandis GK, Saridogan E, Windsor AC, Gulumser C, Cohen CR, Cutner AS. Short-term outcome of fertility-sparing laparoscopic excision of deeply infiltrating pelvic endometriosis performed in a tertiary referral center. *Fertil Steril* 2010; **93**:39–45.
- Pereira RM, Zanatta A, Preti CD, de Paula FJ, da Motta EL, Serafini PC. Should the gynecologist perform laparoscopic bowel resection to treat endometriosis? Results over 7 years in 168 patients. *J Minim Invasive Gynecol* 2009; **16**:472–479.
- Roman H, Opris I, Resch B, Tuech JJ, Sabourin JC, Marpeau L. Histopathologic features of endometriotic rectal nodules and the implications for management by rectal nodule excision. *Fertil Steril* 2009; **92**:1250–1252.
- Ruffo G, Scopelliti F, Scioscia M, Ceccaroni M, Mainardi P, Minelli L. Laparoscopic colorectal resection for deep infiltrating endometriosis: analysis of 436 cases. *Surg Endosc* 2010; **24**:63–67.
- Seracchioli R, Manuzzi L, Mabrouk M, Solfrini S, Frasca C, Manferrari F, Pierangeli F, Paradisi R, Venturoli S. A multidisciplinary, minimally invasive approach for complicated deep infiltrating endometriosis. *Fertil Steril* 2010; **93**:1007.e1–1007.e3.